

Long-Term Psychological and Neurological Complications of Lindane Poisoning

RICHARD C.W. HALL, M.D.

RYAN C.W. HALL, B.A.

This report documents a long-term case of severe hexachlorocyclohexane (lindane) poisoning in which, despite prompt medical treatment, the patient continued to experience neurological and psychiatric symptoms for 20 months after her poisoning.

The neurophysiology of the organochlorines (as they relate to many of this patient's symptoms), the proper uses of anticonvulsants for organochlorine-induced seizures, and other symptoms are discussed.

The following case is of a person who was acutely intoxicated with Kwell[®], an antiscabies agent, that uses lindane as its active ingredient. Although her initial symptoms were indicative of severe lindane poisoning, what makes the case important are the prolonged and clearly related neurological and psychological symptoms that she experienced for 20 months after her initial poisoning.

Case Report

In February 1996, a 37-year-old registered nurse contracted scabies from her daughter. She applied Kwell[®] on February 2, washing it off the next day as per instructions. Ten days later, she became reinfected and again used the Kwell[®] for a 24-hour period. Three days later, she again developed what she believed were mite bites. At this time, she smeared a considerable quantity of Kwell[®] over her upper body, face, breasts, and under her arms and did not wash it off the following day. About 18 hours after applying the third dose of Kwell[®], she developed a series of acute central nervous system symptoms. She experienced major motor tics, began shaking uncontrollably, had speech and thought difficulties, and experienced a "strange sensation" that something was wrong with her. She developed severe burning paresthesias in her hands and feet, which she also perceived as ice cold. She became acutely nauseated, experienced repeated episodes of projectile vomiting, and began a period of myoclonic jerking (affecting both her arms and legs) that became so severe that she was unable to stand. She was taken to an emergency room, where she experienced profound tonic-clonic movements of her extremities that persisted after

being treated with muscle relaxants. Over several hours, her initial symptoms began to abate and she was discharged home on muscle relaxants.

Eight days after the initial episode, she experienced severe abdominal pain and urethral, bladder, and bowel spasms, which caused both urinary and fecal incontinence. She returned immediately to the emergency room. Her urine was strongly positive for myoglobin, and she was believed to have developed an acute rhabdomyolysis. At this time, there were signs of central nervous system hyperactivity; deep tendon reflexes were 4+; and the patient complained of auditory and "visual hallucinations." She underwent a period of sustained shaking that she was unable to control and complained of unusual tastes in her mouth, as well as foul odors, which nauseated her. The tonic-clonic contractions of her upper extremities increased in severity, being greater on the left than on the right.

Following stabilization of her acute myoglobinuria, the patient was discharged home on Valium (diazepam) 2.5 mg po tid. She began to experience both hypnogogic and hypnopompic hallucinations, as well as nocturnal confusion. Valium helped control her symptoms but, if she missed a dose of Valium, they returned. She experienced myoclonic jerking and twitching, unusual tastes, auditory and visual hallucinations, projectile vomiting, profound diarrhea, disconnected thoughts, and inability to structure her activities, and she began making compulsive automatic gestures. She lost 15 pounds during the following 2 weeks, becoming so profoundly weak that she could not walk. Her paresthesias in both arms and legs worsened, and she began to experience unusual symptoms: her tongue or face would become numb. She developed a total-body eczematous rash and giant hives, for which she was successfully treated with prednisone.

Her severe diarrhea persisted in spite of antidiarrheal medication. She reported episodes of soiling herself at night and was constantly worried that she would lose control of her bladder or bowels. Several physicians were contacted, and there was clear documentation of vaginal, clitoral, rectal, and bladder spasms of a severe nature. She continued on Valium, now 30 mg qd, and the spasms in her left arm and both legs, as well as

Received January 25, 1999; revised February 5, 1999; accepted April 28, 1999. From the Department of Psychiatry, University of Florida, Gainesville. Address correspondence and reprint requests to Dr. R.C.W. Hall, 100 East Sybelia Avenue, Suite 210, Maitland, FL 32751.

Copyright © 1999 The Academy of Psychosomatic Medicine.

Case Reports

her nocturnal leg cramps, lessened. She became less agitated and frightened.

From April 12, 1996, through April 16, 1996, the patient was admitted to a local hospital under the care of an internist, who noted the exposure to Kwell[™]. She was treated with higher doses of oral Valium, intravenous fluids, and oral vitamin B₁. She was seen by a neurologist. An electroencephalogram showed 10 Hz posterior alpha rhythm while awake, with low-amplitude beta activity superimposed anteriorly with an attenuation of background amplitude associated with drowsiness. She was unable to tolerate photic stimulation. Throughout the record were periods of higher amplitude 6- to 7-Hz sustained activity, bilaterally.

When seen on May 1, 1996, the patient reported that she had done well when taking Valium 2 mg po tid and 5 mg at hs. When she tried to cut back on the Valium, she experienced an acute recurrence of her previous symptoms.

Over the course of the next year, she tried on several occasions to lower her Valium dose and had a similar return of symptoms. During this time (July 1996), she was treated for pneumonia with Cefitin[™] (cefuroxime axetil) by an infectious disease specialist. The Cefitin[™] exacerbated her previous symptoms.

When seen on May 23, 1997, her neurologist's diagnosis was "toxic encephalopathy." The neurologist felt that the visual changes, which she had experienced (red-green streaking and halo effects), were caused by an impairment in the occipital lobe, secondary to lindane poisoning. On this date, she reported that her mood had stabilized. She had begun to eat well. Taste had returned to normal. Sexual drive and function had returned to baseline levels. She continued to have occasional muscular fasciculations and "mild" conjugate gaze difficulty involving her left eye. She reported that she was "95% back to normal."

On July 30, 1997, she reported that she had tried to taper and stop her Valium, but had reexperienced the nausea, scintillating scotomata, neuromuscular irritability, cramping, and fasciculations. She reexperienced the turning-in of her left eye and again began to see some unusual colors, this time with a bluish cast. She experienced severe headaches, which disappeared when she resumed Valium treatment.

When seen on December 1, 1997, she reported that all of her symptoms had now abated and she was "back to normal." Her Valium was diminished to 2 mg daily at that time. She continued it for 30 days longer and then discontinued it without any recurrence of symptoms.

Discussion

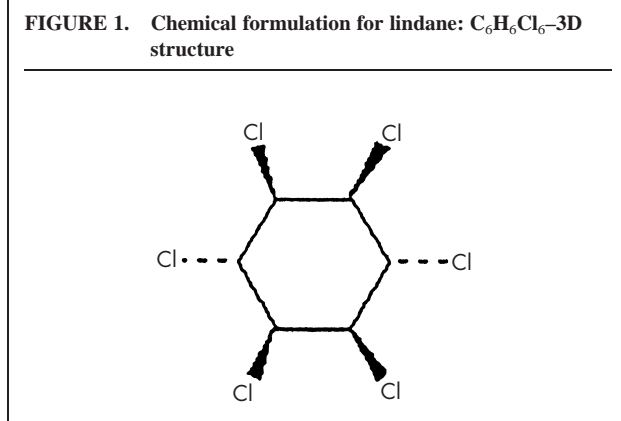
Toxicology of Lindane. BHC (hexachlorocyclohexane) is a widely used insecticide employed to control insect infestations on livestock, pets, humans, and agricultural products. BHC is a mixture of isomers, of which the α - and γ -isomers are central nervous system stimulants, while the β - and δ -isomers are central nervous system depressants. Of all the isomers, the γ -isomer (lindane) has the highest acute toxicity in humans.¹⁻⁴ Lindane's 3-D structure is

shown in Figure 1. The average lethal dose in humans is 125 mg/per kg.^{3,4}

Lindane-containing lotions and shampoos are available by a variety of brand names, including Gamene[™], Kwell[™], Bio-Well[™], G-Well[™], GBH[™], Kildane[™], Scabene[™], and Thionex[™]. The FDA's current recommendations are that lindane-containing products only be used after patients have either failed to respond to adequate doses of other treatments or have been shown to be intolerant of other approved therapies for scabies and mites. Lindane has been banned in 18 countries and is severely restricted in 10 others. Reed and Carnick, the makers of Kwell[™], stopped marketing its lindane product in 1995; however, many pharmacies still have Kwell[™] as part of their shelf inventory. In addition, a variety of generic brands of lindane are still available.

Lindane represents a powerful contact and internal poison, which can be absorbed through skin, inhaled when in vapor form, or consumed orally. The agent is a possible cumulative carcinogen and mutagen. It has teratogenic, immunotoxic, and neurotoxic properties.⁴ Lindane and other organochlorine insecticides have been shown on repetitive exposure to produce hepatic, neuronal, renal, and testicular damage, as well as bone marrow disorders, peripheral paresthesias and neuropathies, muscular weakness, impaired coordination, aplastic anemia, and agranulocytopenia.³⁻¹⁵ The substance damages developing fetuses and may decrease fertility in females.^{1-11,13,14,16,17}

Products containing lindane are all carefully labeled to warn against its use by infants, pregnant women, and nursing mothers. Patients are warned about reapplication, as deaths have been reported following several applications.¹⁸ Dieting women and patients with eating disorders are at greater risk for long-term poisoning. This increased risk of side effects is particularly evident in patients on a



protein-deficient diet.¹ The patient in our report paid careful attention to her weight and consumed a predominantly vegetarian diet, which may have been a factor in her prolonged toxicity.

The onset of signs and symptoms following exposure to hexachlorocyclohexane insecticides and their resulting poisonings vary, depending on the weight of the person, metabolism, serum protein levels, and the route and degree of exposure, as well as whether there are single or multiple exposures to the agent that can prolong the extent of the poisoning.¹⁹ The time interval between high dose exposure and the onset of symptoms is generally less than 12 hours when exposure is gradual, as through skin contact.^{13,14,19} The symptoms produced by these agents may last for weeks to months and patients often experience periodic relapses despite adequate therapy because of the initial lipid storage and subsequent redistribution of these chemicals.¹⁹ Following partial recovery from an exposure, patients evidence an increased susceptibility to subsequent reexposure for about 3 months.^{3-5,20-22}

Table 1 shows the symptoms experienced by our patient throughout the course of her poisoning.

Pathophysiology of Chlorinated Hydrocarbon Poisoning.

In the central nervous system, lindane acts as a noncompetitive gamma-aminobutyric acid (GABA) antagonist. It has been shown that the inhibitory neurotransmitter's and

glycine directly cause an increase in the conductance to Cl⁻ by bonding to ligand-operated ion channel receptors at the postsynaptic membrane. The opening of these Cl⁻ channels usually leads to a net hyperpolarization of the cell. The GABA(A) receptor has separate, but allosterically interacting, binding sites for GABA, benzodiazepines, barbiturates, anesthetic steroids, and the convulsant picrotoxin. The GABA(C) receptor also forms a Cl⁻ channel, but it has been noted that its pharmacology differs significantly from that of the GABA(A) receptor. Lindane produces central nervous system disruption through a variety of mechanisms, the most important being its ability to act as a noncompetitive GABA antagonist interacting with the picrotoxin site, both in membranes and in intact cultured neurons, thereby inhibiting the GABA-induced Cl⁻ flux following activation of either the GABA(A) or GABA(C) receptor.²³⁻²⁸

Lindane is heterogeneously distributed throughout the brain, obtaining higher concentrations in white than grey matter, with its concentration increasing over time. The highest concentrations of lindane are found in the thalamus, midbrain, and pons-medulla. Its affinity for white matter and myelinated structures is related to its lipophilic properties and behavior.^{29,30}

Rosa et al. demonstrated that lindane induces significant changes in the intracellular Ca²⁺ homeostasis of central neurons and has a profound effect in the cerebellum.

TABLE 1. Classification of patient's signs and symptoms according to receptor site and type

Muscarinic (Duration)	Nicotinic (Duration)	Central (Duration)
Headache—	Muscle fasciculations of striated muscle—	Confusion—M
Nausea—M	Profound muscle weakness—S	Seizures—M
Diarrhea—L	Persistent moderate muscle weakness—M	Fatigue—L
Abdominal pain w/cramps—L	Muscle spasm and extensor/flexor imbalance—L	Dysarthria—M
Diaphoresis—I	Tachycardia—M	Ataxia—M
Urinary incontinence—L	Pallor—S	Anxiety—L
Fecal incontinence—L	Myoclonic jerks—L	Depression—L
		Intrusive thoughts—L
		Word-finding difficulty—L
		Memory impairment—L
		Peripheral neuropathy w/ paresthesias and weakness of extremities—L
		Incoordination—L
		Scintillating scotomata—L
		Red/green visual changes—L
		Musical hallucinations—L
		Hypnopompic and hypnogogic hallucinations—L
		Distortion of size of body parts—L
		Amblyopia—M
		Anorexia—M

Note: I = immediate; S = short-term/days; M = mid-term/weeks; L = long-term/months.

Case Reports

Lindane primarily affects the dantrolene-sensitive intracellular Ca²⁺ stores, causing a release of calcium from these stores and altering the sensitivity of membranes.³¹

Sunol et al. demonstrated that the neurotoxic effects of lindane are predominantly mediated through its non-competitive antagonism of the GABA(A) receptor. It was noted that following poisoning and seizure, the concentrations of dopamine and its primary metabolite (DOPAC: dihydrophenyl cetic acid) were increased throughout the mesencephalon and the striatum.³² In cases of chronic intoxication, dopamine levels fluctuated. These fluctuations, following repetitive exposure to lindane, may account for some of the Parkinsonian-like symptoms our patient experienced.

Sanfeliu et al. demonstrated that repetitive, low-level, nonconvulsant doses of lindane produced long-term changes in cerebral 2-14C-deoxyglucose uptake throughout the subcortical structures of the brain, but particularly in the dorsal cochlear nucleus and the dentate gyrus. The researchers suggested that these increases in uptake in the subcortical regions of the brain, mainly related to the limbic system (e.g., Ammon's horn, dentate gyrus, septal nuclei, nucleus accumbens, olfactory cortex) and associated with a diminished uptake in other regions (particularly the auditory and motor cortices), are responsible for the functional alterations (mood, affect, sensations) seen during the course of long-term lindane poisoning.³³

Tilson et al. noted that certain commonly used antiepileptic agents, particularly Dilantin (phenytoin), should be avoided in cases of lindane poisoning, and Valium should be used instead to control symptoms. The researchers noted that animals pretreated with Dilantin, which were then exposed to lindane, had their central nervous system hyperactivity increased rather than lowered by the Dilantin. This was true for both convulsant and subconvulsant doses of lindane. Subconvulsant doses produced an enhanced responsiveness to acoustic stimuli in the animals and increased agitation.³⁴

Studies in animals after exposure to various insecticides in which convulsions occur, show small pyknotic hippocampal neurons and vacuolization of neutrophils. These changes are similar to changes that have been observed in humans dying after status epilepticus. These lesions occur in the frontal cortex, entorhinal cortex, amygdala, caudate nucleus, and hippocampus.²¹ Ischemic changes are particularly pronounced in the white matter. Early treatment with

benzodiazepines, particularly diazepam, has been shown to reduce the incidence and extent of these pathological changes and to speed recovery in surviving animals.^{21,22}

Attia et al. have shown that chronic lindane poisoning causes an enhanced nighttime rise in pineal N-acetyltransferase (NAT) activity and increased central melatonin secretion, as well as increased serum melatonin levels. Chronic lindane poisoning also caused a significant reduction in central serotonin (5-HT) and 5-hydroxyindole acetic acid (5-HIAA).³⁵ This change in central serotonin may well be the factor that mediates the anxiety and depressive changes seen in our patient, as well as the disruption of her sleep cycle.

Nedkova-Bratanova et al. have shown that chronic lindane poisoning, even at low levels, diminishes dipeptidase activity and disrupts the activity of the intestinal disaccharidases for up to 90 days following low-level poisoning. Sucrase is the most effected disaccharidase. This disruption of the disaccharidases may be responsible for the persistent diarrhea experienced by our patient.³⁶

Summary

A thin, healthy, partial-vegetarian, white female, who was exposed to three doses of lindane (through the application of Kwell[®]), developed a severe case of long-term lindane poisoning. Review of the literature suggests that her toxicity was so severe because of the repetitive nature of her exposure and the fact that she was partly protein restricted when first exposed. She developed profound central nervous system toxicity, as well as skin and gastrointestinal changes, that persisted for 20 months. She was treated with high doses of Valium. It was noted that every time her Valium was diminished below a critical level, her symptoms tended to recur until she had adequately cleared the lindane from her system. We believe this is the longest term of poisoning reported following exposure to an organochloride insecticide. Her symptoms are well explained by the physiology of these compounds as described in the literature. The case is important, for it represents the longest persistence of symptoms clearly associated with poisoning by the potent gamma isomer of BHC-lindane.

The authors thank Marcia Chapman for editorial and secretarial assistance in manuscript preparation.

References

1. Boyd EM, Chen CP: Lindane toxicity and protein-deficient diet. *Arch Environ Health* 1968;17:156–163
2. U.S. Department of Health and Human Services: Fourth Annual Report on Carcinogens, Summary, 1985 (Publ No NTP 85–002). Washington, DC, Public Health Service, NPT, 1985, pp. 85–102
3. Gosselin RE, Smith RP, Hodge H: *Clinical Toxicology of Commercial Products*, 5th Edition. Baltimore, MD, Williams & Wilkins, 1984, pp. 239–241
4. Hayes WJ Jr: *Pesticides Studied in Man*. Baltimore, MD, Williams & Wilkins, 1982
5. Danopoulos E, Melissino K, Katsas G: Serious poisoning by hexachlorocyclohexane. Clinical and laboratory observations on five cases. *Archives of Industrial Hygiene & Occupational Medicine* 1953; 8:582–587
6. Friberg L, Martensson J: Case of panmyelophthisis after exposure to chlorophenothane and benzene hexachloride. *Archives of Industrial Hygiene & Occupational Medicine* 1953; 8:166–169
7. Gewin HM: Benzene hydrochloride and aplastic anemia. *JAMA* 1959; 171:1624–1625
8. Lee B, Groth P: Scabies: transcutaneous poisoning during treatment (letter). *Pediatrics* 1977; 59:643
9. Loge JP: Aplastic anemia following exposure to benzene hexachloride (lindane). *JAMA* 1965; 193:110–114
10. Munk ZM, Nantel A: Acute lindane poisoning with development of muscle necrosis. *Can Med Assoc J* 1977; 117:1050–1054
11. Nicholls RW: A case of acute poisoning by benzene hexachloride. *Med J Aust* 1958; 1:42–43
12. West I: Lindane and hematological reactions. *Arch Environ Health* 1967; 15:97–101
13. Wilson JS: Lindane poisoning in a family (editorial). *Med J Aust* 1959; 2:684
14. Ginsburg CM, Lowry W, Reisch JS: Absorption of lindane (gamma-benzene hexachloride) in infants and children. *J Pediatr* 1977; 91:998–1000
15. Fullerton CS, Ursano RJ: Behavioral and psychological responses to chemical and biological warfare agents. *Milit Med* 1999;155:54–49
16. Starr HG Jr, Clifford NJ: Acute lindane intoxication. *Arch Environ Health* 1972; 25:374–375
17. Berry DH, Brewster MA, Watson R, et al: Untoward effects associated with lindane abuse. *Am J Dis Child* 1987; 141:125–126
18. Joselin EF, Forney RI, Huntington RW, et al: A fatal case of lindane poisoning (published privately, 1960). Proceedings of 1958 Seminar of National Association of Coroners.
19. Morgan D: Recognition of management of pesticide poisonings (Publ No EPA–540/9–80–005). Washington, DC, Environmental Protection Agency, U.S. Government Printing Office, 1982
20. U.S. Departments of the Army, Navy, and Air Force Field Manuals 8–285: Treatment of chemical agent casualties and conventional military chemical injuries. HQDA (DASG–HCD), 5109 Leesburg Pike, Falls Church, VA 22041–3258
21. Technical Memorandum 90–3: Clinical notes on chemical casualty care. U.S. Army Medical Research Institute of Chemical Defense, Aberdeen Proving Ground, MD, 1990
22. National Research Council: Possible long-term health effects of short-term exposure to chemical agents. Washington, DC, National Academy Press, 1982
23. Sunol C, Vale C, Rodriguez-Farre E: Polychlorocycloalkane insecticide action on GABA- and glycine-dependent chloride flux. *Neurotoxicology* 1998; 19:573–580
24. Pomes A, Rodriguez-Farre E, Sunol C: Effects of organochlorine pesticides on ^{36}Cl – flux in primary neuronal cultures. *Neurotoxicology* 1994; 15:745–749
25. Aspinwall LS, Bermudez I, King LA, et al: The interactions of hexachlorocyclohexane isomers with human gamma-aminobutyric acid(A) receptors expressed in *Xenopus* oocytes. *J Pharmacol Exp Ther* 1997; 282:1557–1564
26. Nagata K, Huang CS, Hamilton BJ, et al: Differential effects of exachlorocyclohexane isomers on the GABA receptor subunits expressed in human embryonic kidney cell line. *Brain Res* 1996; 738:131–137
27. Nagata, K, Narahashi T: Differential effects of hexachlorocyclohexane isomers on the GABA receptor-chloride channel complex in rat dorsal root ganglion neurons. *Brain Res* 1995; 704:85–91
28. Martinez E, de Vera N, Artigas F: Differential response of rat brain polyamines to convulsant agents. *Life Sci* 1991; 48:77–84
29. Sanfeliu C, Camon L, Martinez E, et al: Regional distribution of lindane in rat brain. *Toxicology* 1988; 49:189–196
30. Joy RM, Albertson TE: Factors responsible for increased excitability of dentate gyrus granule cells during exposure to lindane. *Neurotoxicology* 1987; 8:517–527
31. Rosa R, Sanfeliu C, Sunol C, et al: The mechanism for hexachlorocyclohexane-induced cytotoxicity and changes in intracellular Ca^{2+} homeostasis in cultured cerebellar granule neurons is different for the gamma- and delta-isomers. *Toxicol Appl Pharmacol* 1997; 142:31–39
32. Sunol C, Tusel, JM, Gelpi E, et al: Convulsant effect of lindane and regional brain concentration of GABA and dopamine. *Toxicology* 1988; 49:247–252
33. Sanfeliu C, Sola C, Carmon L, et al: Regional changes in brain 2–14C-doxyglucose uptake induced by convulsant and non-convulsant doses of lindane. *Neurotoxicology* 1989; 10:727–742
34. Tilson HA, Hong JS, Mactutus CF: Effects of 5,5-diphenylhydantoin (phenytoin) on neurobehavioral toxicity of organochlorine insecticides and permethrin. *J Pharmacol Exp Ther* 1985; 233:285–289
35. Attia AM, Richardson BA, Rodriguez C, et al: Lindane may enhance nocturnal pineal N-acetyltransferase activity via beta-adrenergic receptors. *Brain Res* 1991; 554:253–256
36. Nedkova-Bratanova N, Ivanov E, Savov G, et al: Effect of the pesticides phosalone and lindane on the activity of some dipeptidases and disaccharidases in rat intestinal mucosa. *Enzyme* 1979; 24:281–284